

Changing the Convexity and Concavity of Nasal Cartilages and Cartilage Grafts with Horizontal Mattress Sutures: Part II. Clinical Results

Ronald P. Gruber, M.D., Farzad Nahai, M.D., Michael A. Bogdan, M.D., and Gary D. Friedman, M.D.

San Francisco, Calif.

Horizontal mattress sutures have previously been shown to remove unwanted bulbosity and convexity of nasal tip cartilages. The purpose of this study was to extend that concept by investigating the universal applicability of the horizontal mattress suture to change and control the curvature (e.g., convexity or concavity) of a wide variety of nasal cartilages and warped cartilage grafts. The horizontal mattress suture was applied to a variety of clinical situations, including nasal tip bulbosity caused by convex lateral crura, collapsed external nasal valves, warped grafts and struts, crooked L-shaped septal struts, and collapsed internal nasal valves. Twenty-nine cases were studied over a period of 10 to 23 months. The horizontal mattress suture proved to be a simple, effective means of achieving satisfactory control of the curvature of various cartilages of the nose (including external valves, internal valves, and septum) and warped cartilage grafts. Curvature control was obtained in all cases where the cartilage was supple. Moreover, the resultant strength was increased above normal. Partial recurrence of the curvature was seen in only two cases. Clinical results indicated that the horizontal mattress suture is *universally applicable* to a variety of situations in which the curvature of nasal cartilage and cartilage grafts needs to be removed or modified. The mattress suture drastically reduces the need for

scoring (with its inherent problems of weakness) and the need for cartilage grafting. (*Plast. Reconstr. Surg.* 115: 595, 2005.)

Controlling the curvature (convexity or concavity) of nasal cartilages and cartilage grafts has always been a frustrating problem. Mustardé¹ and Tardy et al.² used various mattress suture techniques to modify the shape of prominent ear cartilages. Byrd et al.³ used a vertical mattress suture to control the curvature of the nasal septum. Meyer et al.⁴ and others⁵⁻⁷ used what is in effect a mattress suture technique to open the internal nasal valve of the upper lateral cartilages. Other studies involving aesthetic rhinoplasty have also shown that suture techniques can be extremely helpful, for example, the lateral crural mattress suture⁸ for removing the convexity of the lateral crus, resulting in correction of (along with sutures for the dome^{9,10}) almost all bulbous or broad tip noses.

The purpose of this study was to apply the horizontal mattress suture to a wide variety of situations in which there was unwanted curvature, particularly convexities. Concavities in nasal cartilages are also occasionally difficult to correct. However, because a concavity is always associated with a convexity on the opposite side, mattress suture techniques were expected to be applicable to correction of concavities as well and thus were evaluated.

From Stanford University, the University of California, San Francisco, the Manhattan Eye, Ear, and Throat Hospital, and private practice. Received for publication February 12, 2004; revised May 10, 2004.

DOI: 10.1097/01.PRS.0000150146.04465.81

PATIENTS AND METHODS

The horizontal mattress suture technique was applied in a variety of clinical situations, including nasal tip bulbosity caused by convex lateral crura, collapsed external nasal valves, warped grafts and struts, crooked L-shaped septal struts, and collapsed internal nasal valves. Twenty-nine consecutive cases in which there was abnormal convexity or concavity were chosen. One requirement was that the abnormally curved cartilage be flexible and basically intact. For example, if an abnormally curved lateral crus was largely missing or enveloped in a mass of scar tissue from previous surgery, it was not considered a good candidate for a horizontal mattress suture. All patients were followed for a minimum of 10 months, at which time postoperative photographs of the curvature were compared with the preoperative photographs. Septal deviation was evaluated similarly but also by internal inspection. The internal nasal valve function was evaluated by patient satisfaction and gross airway flow assessment but not rhinomanometry.

RESULTS

Twenty-nine patients (22 female patients and seven male patients) with a variety of clinical problems received horizontal mattress sutures to control the curvature (convexity/concavity) of the nasal cartilages or cartilage grafts (Table I). Follow-up ranged from 10 to 23 months (mean, 15.3 months) and indicated that the long-term success rate appears to be quite good [evaluated by the senior author (Gruber)]. Recurrence of the curvature was partial in only two cases (lateral crus convexity and external valve collapse). There were no

TABLE I

Horizontal Mattress Suture Applications to Control Cartilage Curvature in Various Clinical Situations (follow-up, 10 to 23 months)

Clinical Application	No. of Cases
Bulbous nasal tip (convex lateral crus)	12
External valve collapse	5
Curved cartilage grafts	
Columellar strut grafts	3
Strut for lateral crus reconstruction	1
Tip grafts	2
Crooked septum	
Vertical component of L-shaped strut	3
Horizontal component of L-shaped strut	1
Collapsed internal nasal valve	2
Total	29

instances of suture infection, suture reaction, suture "spitting," or need to remove sutures.

Bulbous or Broad Tip (Lateral Crus Convexity)

Lateral crus convexity was by far the most frequent indication for the mattress suture. In a typical bulbous or broad nasal tip, the cephalic component of the lateral crus is resected, leaving a 6-mm lateral crus. Empirically, a 6-mm-wide lateral crus has sufficient stability to prevent external valve collapse. A 6-mm-wide lateral crus is also easy to manipulate with the mattress suture. The vestibular skin is hyperinfiltated with local anesthesia just before inserting the suture. The lateral crus is grasped with Brown-Adson forceps at the apex of the convexity and a P-3 (Ethicon, Inc., Somerville, N.J.), 5-0 nylon suture (polydioxanone is an acceptable alternative) is inserted on one side of the forceps and perpendicular to the direction of the lateral crus (Fig. 1). The needle entry should be on the caudal side of the lateral crus so that the knot ends up on that side (rather than the cephalic side, where it is more likely to be palpable).

The average lateral crus being 0.5 mm thick, the second purchase is performed approximately 6 to 8 mm away. In our previous work (part I), we had found this distance to be appropriate for convexity correction for cartilage

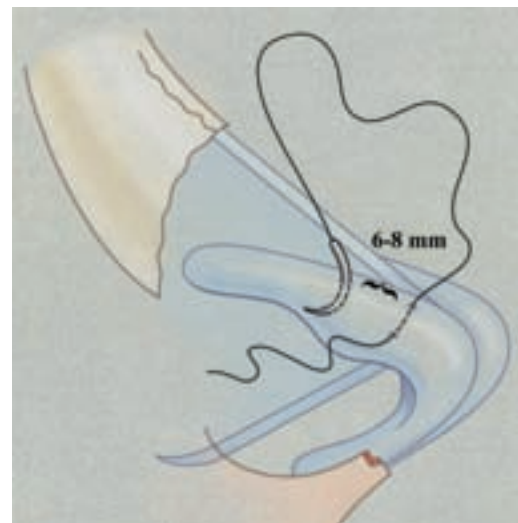


FIG. 1. To correct convexity of the lateral crus (responsible for a bulbous nasal tip), a horizontal mattress suture is inserted. The needle with 5-0 nylon (or polydioxanone) suture is passed perpendicular to the length of the lateral crus. A second purchase is made 6 to 8 mm from the first purchase. As the knot is tied, the convexity disappears. If the convexity extends from one end of the lateral crus to the other, two mattress sutures may be needed, one adjacent to the other.

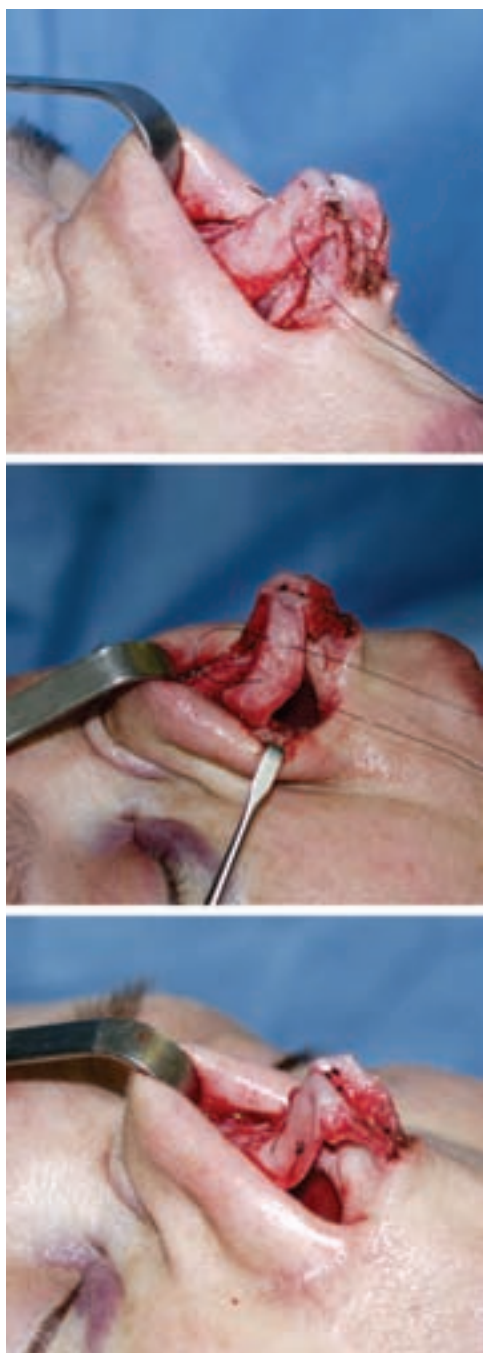


FIG. 2. Intraoperative example of mattress suture for the lateral crus. The vestibular skin is hyperinfiltrated with local anesthesia. The first purchase is made perpendicular to the length of the lateral crus (*above*). The spacing between suture purchases is approximately 6 to 8 mm (*center*). As the suture is tightened, the convexity disappears (*below*).

of this thickness. Two throws are made with the needle holder and the knot is tightened until the lateral crus appears to be flat (Fig. 2). If the lateral crus is convex from one end to the other, a second mattress suture is placed adja-

cent to the first to correct convexity not corrected by the first suture.

An unanticipated feature of the horizontal mattress suture to correct an aesthetic deformity of the lateral crus is its simultaneous minor but apparently significant effect on the posterior aspect of the lateral crus. As the mattress suture knot is tightened, the convexity subsides and the posterior aspect of the lateral crus moves laterally. Apparently, the mattress suture imposes a vector force (Fig. 3) on the posterior aspect of the lateral crus that causes it to move laterally. Figure 4 provides preoperative and postoperative results of the aesthetic changes that were achieved with a lateral crus mattress suture.

Alar, External Valve Collapse (Lateral Crus Concavity)

A number of patients exhibit concavity deformities of the lateral crus. Some are congenital. Most are iatrogenic following excessive resection, excessive scoring, or overtransection of the cephalic component of the lateral crus. The net result is an external deformity and/or an airway obstruction (collapsed external valve).

In the open approach, the lateral crus and its concavity are easily visualized. If it appears that the existing lateral crus has substantial length and width (e.g., at least 5 mm), the vestibular skin is hyperinfiltrated. The posterior end of the lateral crus is transected and the lateral

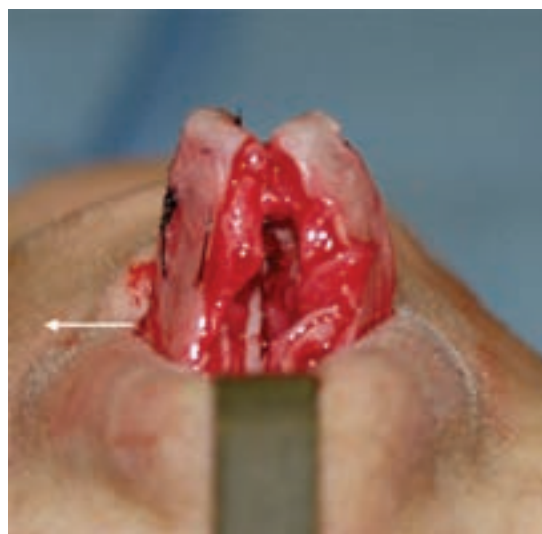


FIG. 3. A horizontal mattress suture to correct the aesthetic convexity of the lateral crus simultaneously improves the functionality of the external valve. As the knot of the suture is tightened, a vector force moves the posterior aspect of the lateral crus laterally.

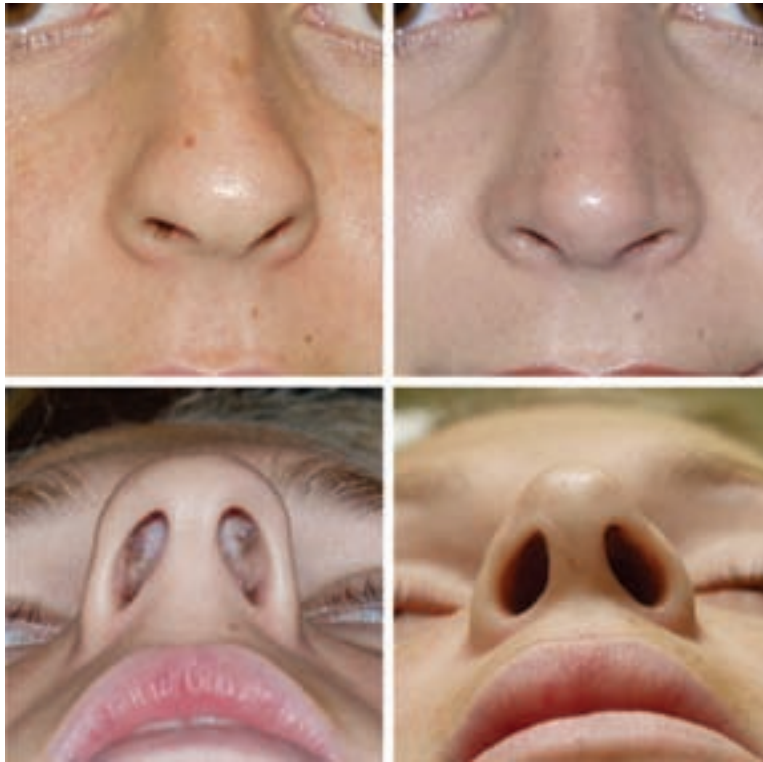

FIG. 4. Preoperative views of a bulbous nasal tip (*above, left, frontal view; below, left, basal view*). The patient received cephalic resection of the lateral crus, leaving a 6-mm-wide lateral crus, transdomal sutures, and mattress sutures for the lateral crus bulbosity. At 14 months postoperatively (*above, right, frontal view; below, right, basal view*), there is significant improvement in tip bulbosity.

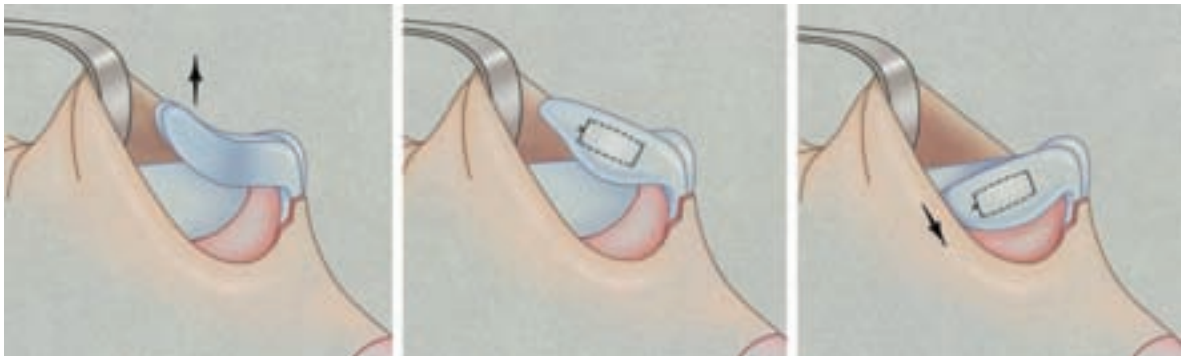


FIG. 5. In the open approach, the collapsed (concave) lateral crus is corrected by first hyperinfiltrating the vestibular skin with local anesthesia. The posterior end of the lateral crus is transected and the crus is elevated off the vestibular skin from lateral to medial, exposing that part of the lateral crus that is deformed (*left*). A mattress suture is placed on the vestibular side where it is convex (*center*) and the lateral crus is sutured back to the vestibular skin with absorbable sutures (*right*).

crus is dissected off the vestibular skin. A mattress suture is placed on the vestibular side where the convexity is maximal (Figs. 5 through 7). Placement is virtually identical to the method used to correct the convexity of bulbous nasal tips. In this case, however, the mattress suture is placed on the other side of the lateral crus. If, however, after elevation of

the lateral crus from the vestibular skin the resultant crus does not have substantial length or width, a Gunter-type strut is placed on the vestibular side.¹¹⁻¹³

In the closed approach, the vestibular skin is hyperinfiltrated with local anesthesia and a flap of vestibular skin is elevated off the cartilage (Fig. 8, *above*). The flap is anteriorly based and

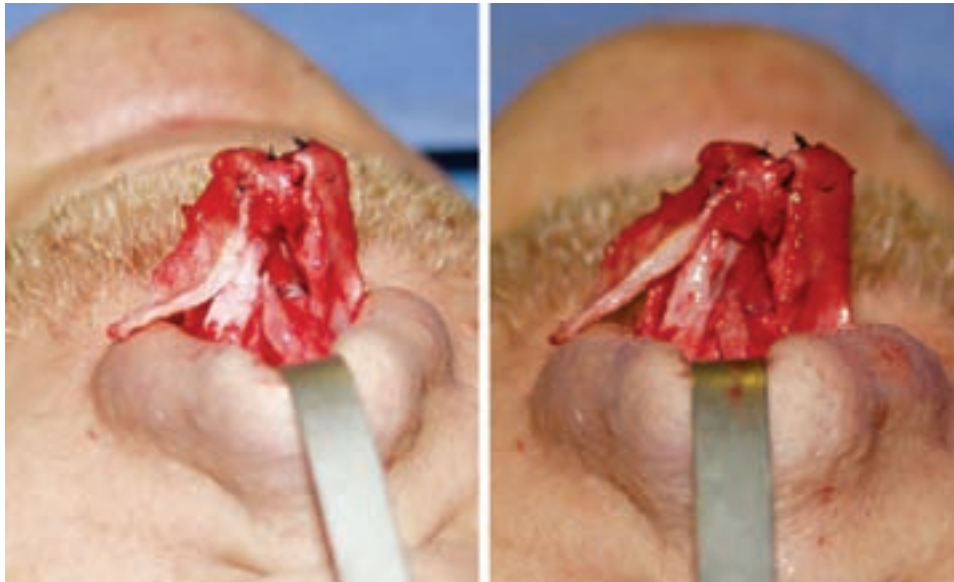


FIG. 6. Intraoperative views before (*left*) and after (*right*) a horizontal mattress suture is used to correct the concavity of the lateral crus.

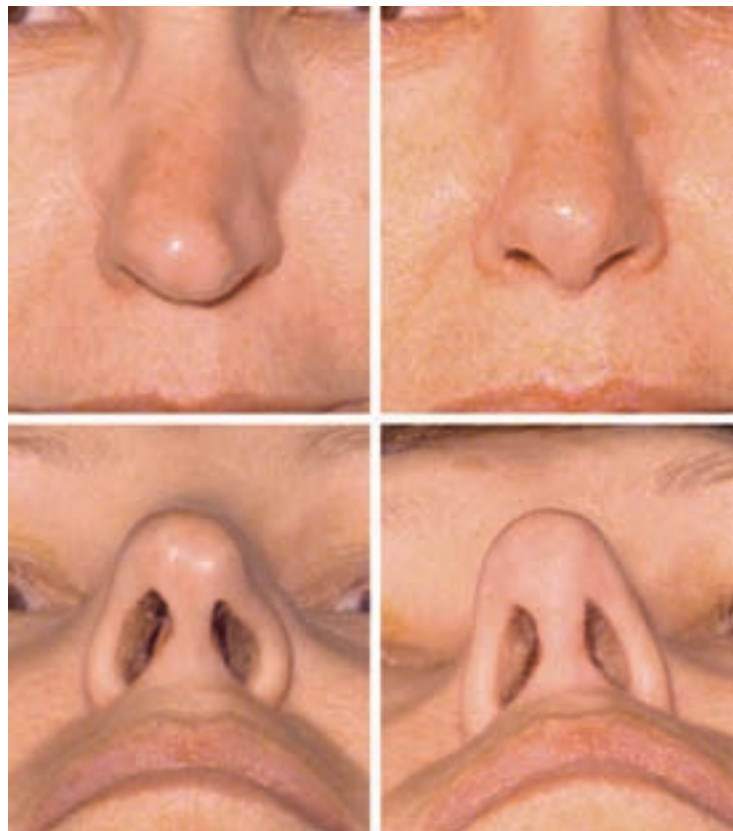


FIG. 7. Preoperative views of a collapsed left external valve and deviated septum (*above, left, frontal view; below, left, basal view*). Postoperative views of rhinoplasty (17 months) including mattress suture to the convex side of collapsed left lateral crus (*above, right, frontal view; below, right, basal view*).

the sides of the flap coincide with the intercartilaginous incision and the “rim” (caudal border of the lateral crus) incision. Thus, the flap

is approximately 2.5 to 3 cm long and 8 mm wide. A mattress suture of 5-0 nylon (or polydioxanone) is placed on the vestibular (con-

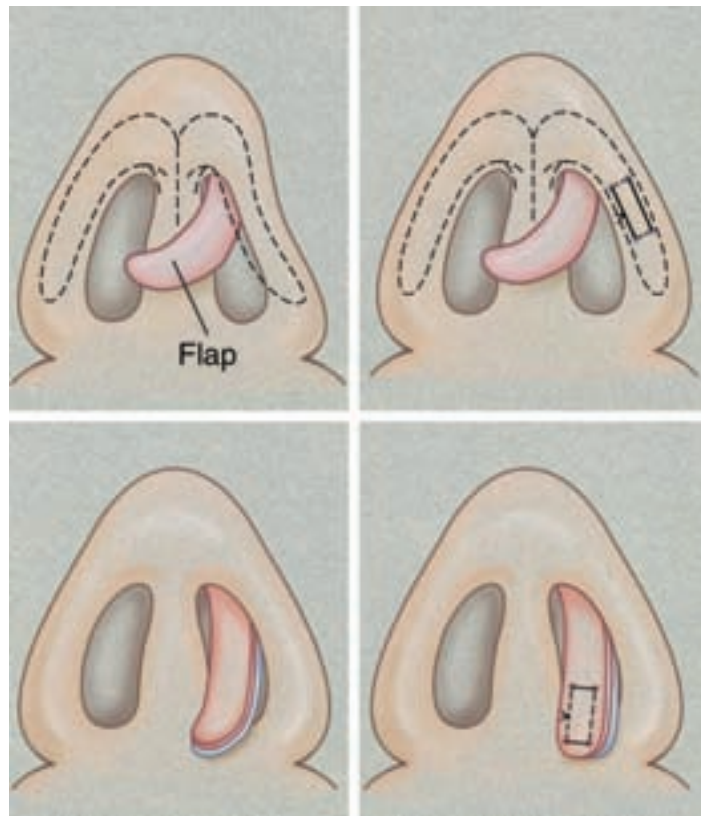


FIG. 8. In the closed approach (when the tip cartilages are not delivered), the vestibular skin is hyperinfiltrated with local anesthesia and a flap of vestibular skin is elevated off the cartilage (*above, left*). A mattress suture of 5-0 nylon (or polydioxanone) is placed on the vestibular (convex) side of the collapsed lateral crus (*above, right*) and the flap is replaced. Some lateral crura obstruct the airway when the posterior end protrudes into the vestibule. A full-thickness flap of vestibular skin and lateral crus is raised (*below, left*). The flap is anteriorly based and the sides of the flap are an intercartilaginous incision and a rim (caudal aspect of lateral crus) incision. A mattress suture is then placed on the convex side of the flap to straighten it (*below, right*).

vex) side of the collapsed lateral crus and the vestibular flap is replaced with interrupted 5-0 plain catgut sutures.

If for any reason the tip cartilages have to be delivered by rim and intercartilaginous incisions, concavities in the lateral crus are approached by the same method as in the open approach. After hyperinfiltrating the vestibular skin with local anesthesia, the lateral crus is transected at its most posterior end and elevated off the vestibular skin. So doing exposes the convex side of the collapsed lateral crus. A horizontal mattress suture (or two) is inserted and the straightened lateral crus is returned to its original location (Fig. 8, *below*).

Some lateral crura obstruct the airway when the posterior end protrudes into the vestibule (Fig. 7, *right*). In this situation, the vestibular side of the lateral crus is concave. To correct it,

a full-thickness flap of vestibular skin and lateral crus is raised. The flap is anteriorly based and the sides of the flap are an intercartilaginous incision and a rim (caudal aspect of lateral crus) incision. A mattress suture can then be easily placed on the convex side of the flap to straighten it.

Curved Cartilage Grafts (Struts, Tip Grafts)

Ear cartilage that is used for struts is seldom flat. To make it flat, the concha cymba (the upper half of the concha) is separated from the concha cavum. It is then split longitudinally, resulting in two pieces of cartilage, both of which are usually quite curved (Fig. 9). The graft is pinned to a silicone block with no. 30 needles, with the convex side facing up. The silicone block facilitates the application of mattress sutures because it stabilizes the graft and

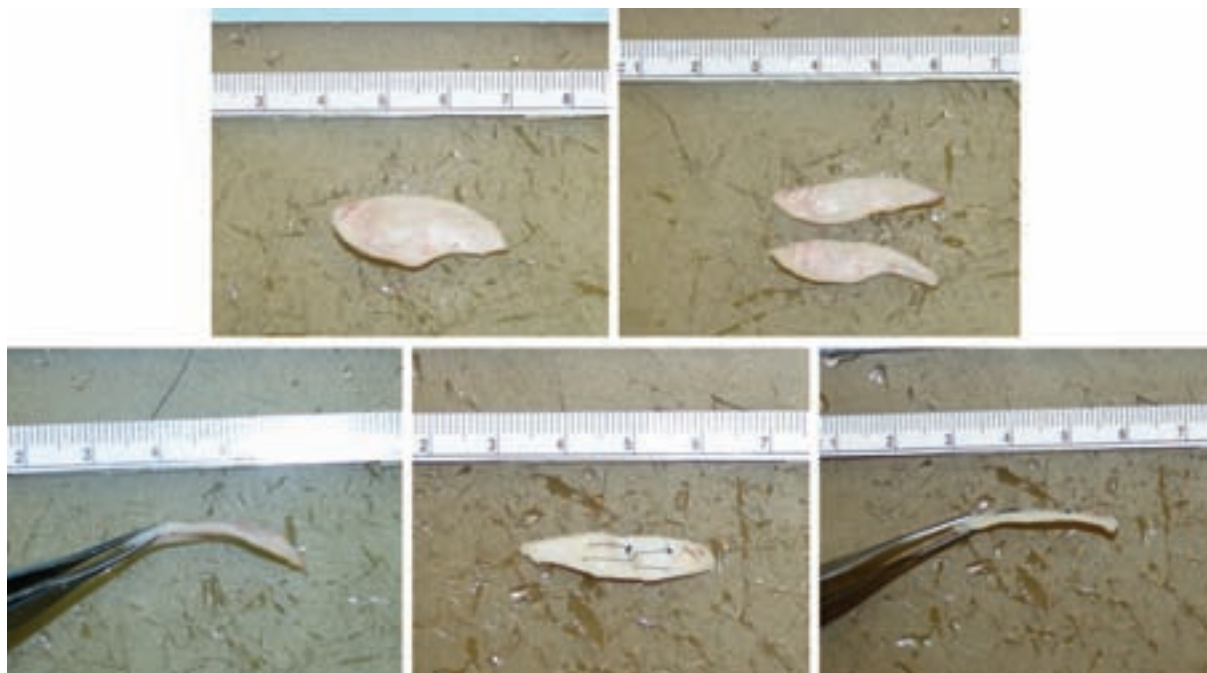


FIG. 9. A columellar strut (2.5×4 to 5×1 mm) is made from the concha cymba of the ear (*above, left*) by splitting it down the middle (*above, right*), leaving a typically warped specimen (*below, left*). It is straightened by pinning it to a silicone block and applying two mattress sutures on the convex side (*below, center*). The convexity is largely eliminated (*below, right*).

allows one to pass a suture needle on the underside of the graft. A P-3 (or smaller) needle with a 5-0 nylon (or polydioxanone) suture is used. The purchase (approximately 3 mm in size) is made by passing the needle perpendicular to the length of the graft. Usually, two mattress sutures are needed to completely straighten the cartilage.

If necessary, a small purchase can be obtained by making two passes with the needle through narrowly separated entry and exit sites. A second purchase of the cartilage is taken with a spacing of 7 to 9 mm from the first purchase. The thicker the cartilage, the wider the spacing should be. If the specimen is long and curved from one end to the other, more than one mattress suture may be necessary. We made struts for use as columellar struts and struts to reconstruct the lateral crus.

Ear cartilage that is used for a tip graft is usually curved and does not require scoring to act as an ideal tip graft. On occasion, when there is too much curvature in the tip graft (of ear cartilage origin), a mattress suture is applied on the convex side. Normally, tip grafts (of septal origin) are too straight and have to be scored. If they are inadvertently overscored and exhibit too much curvature, a mattress suture is placed on the convex side to restore some of the integrity and desired curvature of the tip graft. This is

done by pinning the ear cartilage to the silicone block and applying the mattress suture as described for the concha cymba.

Crooked Septum (L-Shaped Strut)

A crooked septum is commonly corrected by resecting the central component, leaving an L-shaped strut. If the horizontal component is crooked, it is commonly corrected by scoring in on the concave side. If the scoring technique is applied to a crooked vertical component, it may weaken it to the point of collapse. The mattress suture works well to correct the vertical component of the L-shaped strut (Figs. 10, *above*, and 11). Because septal cartilage in this region can be relatively thick (1 to 1.5 mm), the spacing for the mattress suture is usually 7 to 10 mm. On occasion, a second mattress suture is needed (adjacent to the first) to correct any residual convexity not corrected by the first suture. The horizontal component can also be straightened with a mattress suture (Fig. 10, *below*), and we used it in one patient.

Collapsed Internal Nasal Valve (Upper Lateral Cartilages)

Most iatrogenic internal nasal valve problems are caused by a paucity of cartilage at the apex of the junction between the upper lateral cartilage and the dorsal septum as a result of dorsal resec-

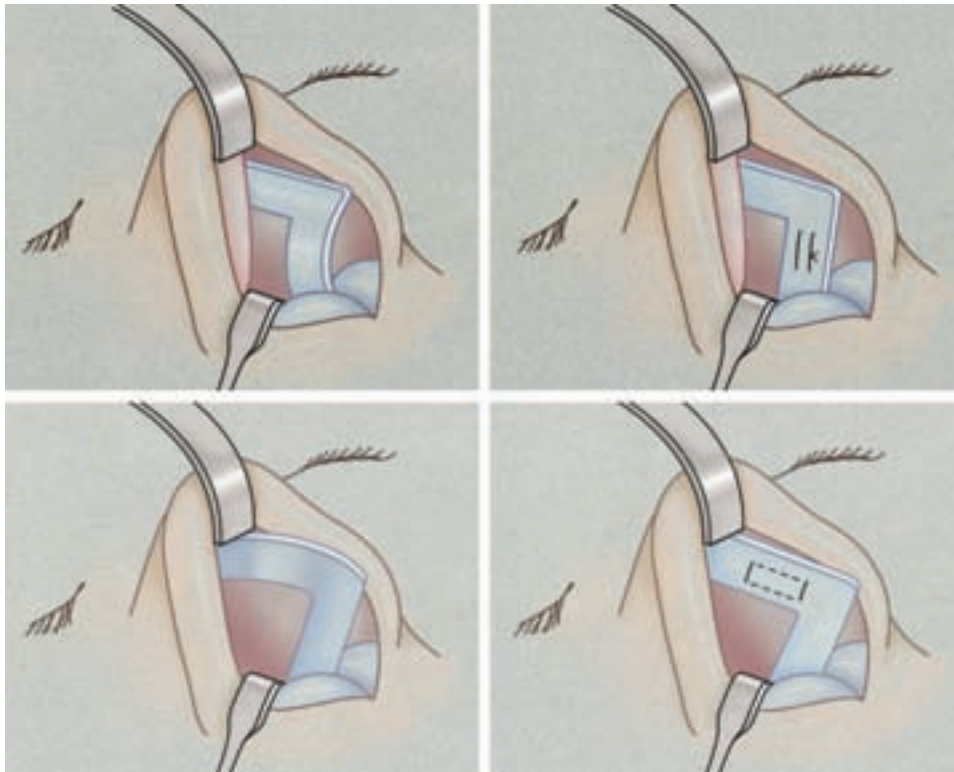


FIG. 10. The crooked vertical component (*above, left*) of the L-shaped strut can be corrected by a mattress suture (*above, right*). The crooked horizontal component (*below, left*) of the L-shaped strut can also be corrected by a mattress suture if necessary (*below, right*).

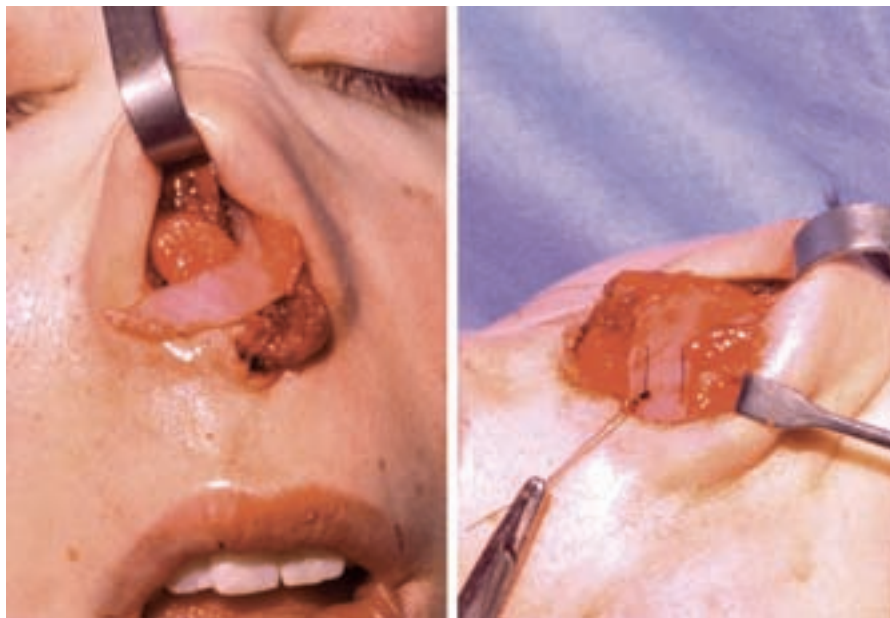

FIG. 11. Intraoperative views of the curved vertical component of an L-shaped septal strut (*left*) demonstrate how the mattress suture straightens the horizontal component of the L-shaped septal strut (*right*). Because septal cartilage in this region can be relatively thick (1 to 1.5 mm), the spacing for the mattress suture is usually 7 to 10 mm.

tion, resulting in a very narrow internal nasal valve angle. The treatment in most cases, therefore, is a Sheen-type spreader graft,¹⁴ which wid-

ens the apex of the angle. In some instances of internal valve incompetence, however, there is ample cartilage in the apex of the internal nasal

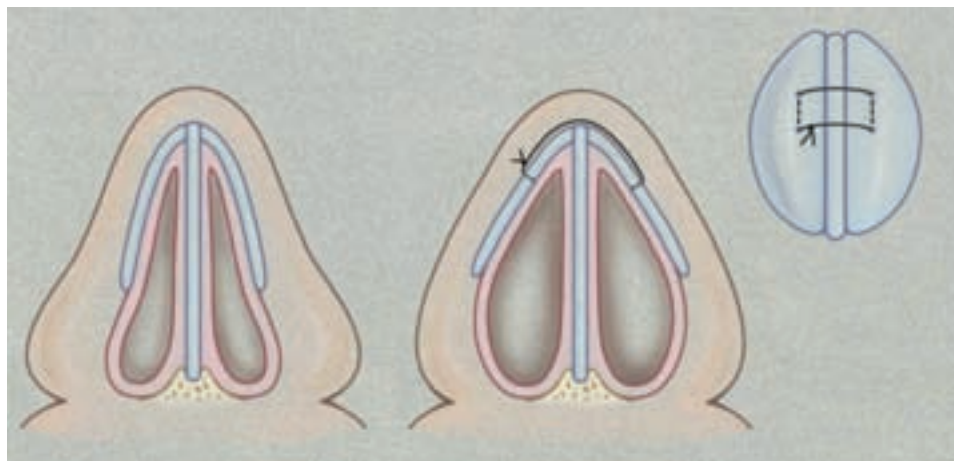


FIG. 12. In some instances of internal valve incompetence, there is ample cartilage in the apex of the internal nasal valve but the wings of the upper lateral cartilages are simply collapsed (hyperconvex). Correction of a collapsed (*left*) internal nasal valve (upper lateral cartilages) can be achieved by applying a mattress suture on the convex surface of the upper lateral cartilages (*right*).

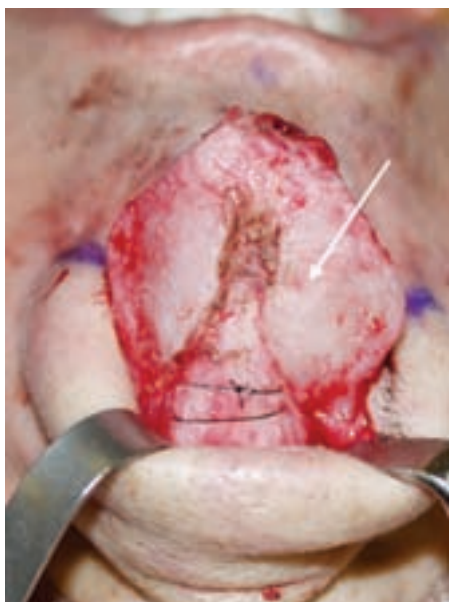

FIG. 13. As the knot of a mattress suture on the (convex) surface of the internal nasal valve is tightened, the wings of the internal nasal valve angle open.

valve but the wings of the upper lateral cartilages are simply collapsed (Figs. 12 and 13). The contour of the upper lateral cartilages is one of hyperconvexity. The problem in this circumstance is to spread the wings by reducing the hyperconvexity. Correction is achieved by applying a mattress suture (4-0 nylon or polydioxanone) on the convex surface of the upper lateral cartilages. As the knot is tightened, the wings (and internal nasal valve angle) open.

DISCUSSION

Universal Applicability of the Mattress Suture

What started out as a single maneuver (horizontal mattress suture) to solve a particular problem for the bulbous nasal tip⁸ has evolved into a generalized concept: virtually all abnormally curved cartilages of the nose can be corrected with one or more mattress sutures. We were able to generalize the satisfactory results obtained with our original use of mattress sutures for bulbous broad tip cartilages to practically every nasal cartilage and cartilaginous graft situation in rhinoplasty.

Analysis of the Cases

Horizontal mattress sutures for the lateral crus have revolutionized our ability to reshape the bulbous, broad, and boxy tip. By leaving a 6-mm-wide lateral crus after trimming the cephalic component, the lateral crus is a stable structure not prone to external valve collapse or alar retraction. Moreover, a 6-mm-wide lateral crus is very amenable to the mattress suture.

Convex lateral crura would appear to resist negative pressure and resist airway obstruction. Any means to correct them, including the mattress suture, may therefore negatively affect the function of the external valve. However, the mattress suture does appear to have two positive features to minimize this potential problem. First, it stiffens the lateral crus to resist negative pressure. Second, it forces the posterior aspect of the lateral crus to move laterally.

This may be a significant benefit when a transdomal suture is used. The transdomal suture (the most commonly used suture to improve the nasal tip cartilages) typically causes some medial displacement of the entire lateral crus including the posterior aspect and therefore partial closure of the external valve. In some cases, patients receiving transdomal sutures have required a lateral crural strut graft¹¹⁻¹³ to correct this secondary deformity. The mattress suture seems to offset part of this particular negative side effect of the otherwise extremely useful transdomal suture. Future studies will be needed to corroborate this impression.

The horizontal mattress suture is not the only way to correct a convex lateral crus. Tebbetts¹⁵ has successfully demonstrated how effective the lateral crural spanning suture is for that purpose. In our hands, however, the lateral crural spanning suture is more difficult to execute because tying the knot produces two effects: lateral crus convexity correction and a narrowing of the width between the lateral crura. During the process of reducing convexity, we have experienced occasional unwanted narrowing of the overall width of the nasal tip. Therefore, we prefer separate control of the curvature.

A collapsed external valve is commonly caused by a concave lateral crus.¹⁶⁻¹⁸ However, because the underside of that concave lateral crus is convex, it is amenable to correction by a mattress suture (two if necessary). In the open approach, the lateral crus must be lifted off the vestibular skin to gain access to the convex side. In the closed approach, a flap of vestibular skin must be lifted off the convex side of the collapsed lateral crus. In either case, the success of the mattress suture depends on a reasonably sized lateral crus. If the lateral crus is largely missing (because of previous overresection) a graft, for example, a lateral crural strut will be necessary. Neu¹⁹ has found success with a variation of the mattress suture concept. He used a series of mattress sutures in chain-link fashion. Although more complicated than the single mattress suture suggested here, the principle is the same.

Because ear cartilage is inherently curved, surgeons have either minimized their use of the ear as a donor site or have crushed and scored the ear cartilage to make a donor graft that is somewhat straight. Unfortunately, crushing and scoring only weaken cartilage, making its use as a strut more difficult and

rendering it susceptible to postoperative warping. The mattress suture has largely resolved this problem by straightening ear cartilage without damaging it. Our modulus results (part I) with cadaver cartilage indicated that sutured grafts are stronger than ever before. The commonest example is when making a columellar strut from concha cymba. By placing one (and if necessary, two) mattress suture on its convex side, the concha cymba becomes a reasonably straight structure, with sufficient rigidity and length to act as a columellar strut.

In past years, the crooked vertical component of an L-shaped columellar septum that required correction was best corrected (straightened) with a batten graft. Scoring, although highly successful for the horizontal component, renders the vertical component weak enough to risk collapse. The use of a mattress suture (placed on the convex side of the vertical component), however, largely straightens that component and provides additional stability. It also minimizes the potential increased thickness to the columellar septum that batten grafts may cause. Although it was not identical to the technique reported here, Kenyon et al.²⁰ used a suture technique to correct the caudal septal cartilage dislocation.

Although we successfully used a mattress suture for the horizontal component in one patient, there are probably not too many indications for straightening the horizontal component with mattress sutures. Scoring procedures and septal straightening sutures that secure the septum to the upper lateral cartilage^{3,21} have rendered that aspect of crookedness a much less important issue.

The concept of spreading the wings of the upper lateral cartilages and thereby opening the internal nasal valve is not new. Guyuron et al.²² and others^{23,24} have chosen to rectify this problem by applying a cartilage graft on the anterior surface of the upper lateral cartilages to act as a spring and spreading the wings of the upper lateral cartilage. Meyer⁴ and others^{6,7} have used horizontal mattress sutures (often referred to as flaring sutures) to widen the internal nasal valve. Park⁵ used vertical mattress sutures. In the closed approach, we have found that a vertical mattress suture is technically much easier to apply. The cases reported here were all performed in the open approach, for which we found the horizontal mattress suture to work best.

It should be acknowledged that most of the time a spreader graft is necessary to widen the apex of the internal nasal valve angle.²⁵⁻²⁷ Moreover, the ability of a mattress suture to open the internal nasal valve angle depends on the cartilage being supple. Previous surgery (hump removal) frequently results in inelastic scar tissue in the apex region of the internal angle. However, if the width of the middle third of the nose is normal yet the airway is suspected of being compromised in this region because of narrow internal nasal valve angles, a horizontal mattress suture is worth trying. Little is lost in the attempt. Clearly, further experimentation with mattress sutures in this region of the nose needs to be performed.

Mattress Suture versus Scoring versus Grafts

The horizontal mattress suture has the potential to control the curvature similar to what a batten graft or strut does, without the complexity of needing to graft and without sacrificing donor sites. Unlike scoring, it is reversible. If the surgeon has overcorrected or undercorrected the curvature, he or she has the option of replacing the suture. Sometimes, a second mattress suture is needed for residual convexities not corrected by the first suture. The mattress suture can even be used to strengthen and correct the curvature of cartilage that results from scoring.^{28,29}

CONCLUSIONS

In this series of patients, there were no suture reactions. Clearly, polydioxanone sutures are less likely to have long-term problems than nylon or other permanent sutures. We tend to favor nylon when there is adequate soft-tissue coverage over it because the knots seem to stay better and one can be reasonably certain that the cartilage change will be permanent. However, in all likelihood, the resultant fibrosis after polydioxanone sutures will be sufficient to maintain the curvature, and the likelihood of infection or rejection will be drastically reduced. The long-term effects of mattress sutures, per se, on the nasal cartilage in our cases are not known. A study by Rohrich et al.³⁰ suggests, however, that these sutures might be stimulating cartilage hyperplasia as in the ear cartilage of their experimental rabbit model. Further application of the mattress suture to the variety of clinical situations outlined here will be needed to verify the success or failure

of long-term results. At this time, the outlook is good.

Ronald P. Gruber, M.D.
3318 Elm Street
Oakland, Calif. 94609
rgrubermd@hotmail.com

ACKNOWLEDGMENT

The authors thank Wendy Jackelow for creation of the schematics.

REFERENCES

1. Mustardé, J. C. The treatment of prominent ears by buried mattress sutures: A ten-year survey. *Plast. Reconstr. Surg.* 39: 382, 1967.
2. Tardy, M. E., Tenta, L. T., and Pastorek, N. J. Mattress suture otoplasty: Indications and limitations. *Laryngoscope* 79: 961, 1969.
3. Byrd, H. S., Salomon, J., and Flood, J. Correction of the crooked nose. *Plast. Reconstr. Surg.* 102: 2148, 1998.
4. Meyer, R., Jovanovic, B., and Derder, S. All about nasal valve collapse. *Aesthetic Plast. Surg.* 20: 141, 1996.
5. Park, S. S. The flaring suture to augment the repair of the dysfunctional nasal valve. *Plast. Reconstr. Surg.* 101: 1120, 1998.
6. Schlosser, R. J., and Park, S. S. Functional nasal surgery. *Otolaryngol. Clin. North Am.* 32: 37, 1999.
7. Ozturan, O., Miman, M. C., and Kizilay, A. Bending of the upper lateral cartilages for nasal valve collapse. *Arch. Facial Plast. Surg.* 4: 258, 2002.
8. Gruber, R. P., and Friedman, G. D. Suture algorithm for the broad or bulbous nose. *Plast. Reconstr. Surg.* 110: 1752, 2002.
9. Rohrich, R. J., and Adams, W. P., Jr. The boxy nasal tip: Classification and management based on alar cartilage suturing techniques. *Plast. Reconstr. Surg.* 107: 1849, 2001.
10. Daniel, R. K. Rhinoplasty: A simplified, three-stitch, open tip suture technique. Part I: Primary rhinoplasty. *Plast. Reconstr. Surg.* 103: 1491, 1999.
11. Gunter, J. P., and Friedman, R. M. Lateral crural strut graft: Technique and clinical applications in rhinoplasty. *Plast. Reconstr. Surg.* 99: 943, 1007.
12. Gruber, R. P. Recognizing and treating alar malposition. *Perspect. Plast. Surg.* 15: 33, 2001.
13. Menick, F. J. Anatomic reconstruction of the nasal tip cartilages in secondary and reconstructive rhinoplasty. *Plast. Reconstr. Surg.* 104: 2187, 1999.
14. Constantian, M. B., and Clardy, R. B. The relative importance of septal and nasal valvular surgery in correcting airway obstruction in primary and secondary rhinoplasty. *Plast. Reconstr. Surg.* 98: 38, 1996.
15. Tebbetts, J. B. Shaping and positioning the nasal tip without structural disruption: A new, systematic approach. *Plast. Reconstr. Surg.* 94: 61, 1994.
16. Courtiss, E. H., and Goldwyn, R. M. The effects of nasal surgery on airflow. *Plast. Reconstr. Surg.* 72: 9, 1983.
17. Teichgraeber, J. F., and Wainwright, D. J. The treatment of nasal valve obstruction. *Plast. Reconstr. Surg.* 93: 1174, 1994.
18. Aiach, G., and Levignac, J. *Aesthetic Rhinoplasty*. Edinburgh: Churchill Livingstone, 1991. P. 18.
19. Neu, B. R. Suture correction of nasal tip cartilage concavities. *Plast. Reconstr. Surg.* 98: 971, 1996.

20. Kenyon, G. S., Kalan, A., and Jones, N. S. Columelloplasty: A new suture technique to correct caudal septal cartilage dislocation. *Clin. Otol. Allied Sci.* 27: 188, 2002.
21. Guyuron, B., and Behmand, R. A. Nasal tip sutures: Part II. The interplays. *Plast. Reconstr. Surg.* 112: 1130, 2003.
22. Guyuron, B., Michelow, B. J., and Englehardt, C. Upper lateral splay graft. *Plast. Reconstr. Surg.* 102: 2169, 1998.
23. Madison, C. J., and Cook, T. A. The 'butterfly' graft in functional secondary rhinoplasty. *Laryngoscope* 112: 1917, 2002.
24. Stucker, F. J., Lian, T., and Karen, M. Management of the keel nose and associated valve collapse. *Arch. Otol. Head Neck Surg.* 128: 842, 2002.
25. Rees, T. D. *Aesthetic Plastic Surgery*. Philadelphia: Saunders, 1980. P. 71.
26. McKinney, P., and Cunningham, B. L. *Rhinoplasty*. New York: Churchill Livingstone, 1989. P. 143.
27. Sheen, J. H. Rhinoplasty: Personal evolution and milestones. *Plast. Reconstr. Surg.* 105: 1820, 2000.
28. Fry, H. J. Interlocked stresses in human nasal septal cartilage. *Br. J. Plast. Surg.* 19: 276, 1966.
29. ten Koppel, P. G. J., van der Veen, J. M., Hein, D., et al. Controlling incision-induced distortion of nasal septal cartilage: A model to predict the effect of scoring of rabbit septa. *Plast. Reconstr. Surg.* 111: 1948, 2003.
30. Rohrich, R. J., Friedman, R. M., and Liland, D. L. Comparison of otoplasty techniques in the rabbit model. *Ann. Plast. Surg.* 34: 43, 1995.